

Spur[®] RST Modifies Calcification and Disrupts Lamina

CASE HISTORY

A 51-year-old male, Rutherford Class 5, presented with minor tissue loss (Figure 1) of the 4th digit. His past medical history included Type I Diabetes, previous kidney transplant, coronary artery disease with historical myocardial infarction, congestive heart failure, hypertension, former tobacco use, hyperlipidemia, and a 5th digit amputation on index limb. Baseline Ankle Brachial Index (ABI) was 1.4 and Tibial Brachial Index (TBI) 0.68.

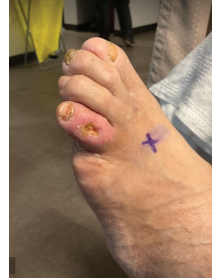

Figure 1

PROCEDURE

Baseline

To ensure healing of the 4th digit wound, posterior flow needed to be optimized to ensure wound healing with the posterior tibial artery as the dominant supply to the foot.

Lesion Characteristics

The lesion was located in the left peroneal artery, lesion length 50 mm (Figure 2). Site reported stenosis was 70–90%, core lab adjudicated stenosis was 76%.

IVUS Baseline

Heavy calcification in the medial layer of the peroneal artery above the area of possible stenosis (Figure 3). Discrete stenosis on angio shows significant soft plaque formation in the lumen with >70% stenosis (Figure 4).

Spur Deployment

The left peroneal artery was treated with the 3.0 x 65 mm Spur Peripheral Retrievable Stent System after lesion predilatation (Figure 5).

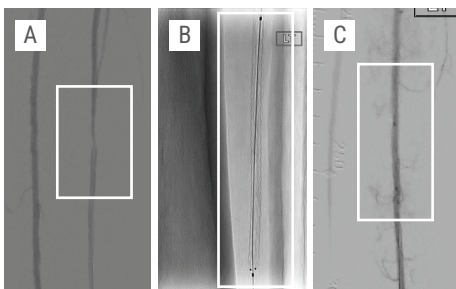


Figure 5

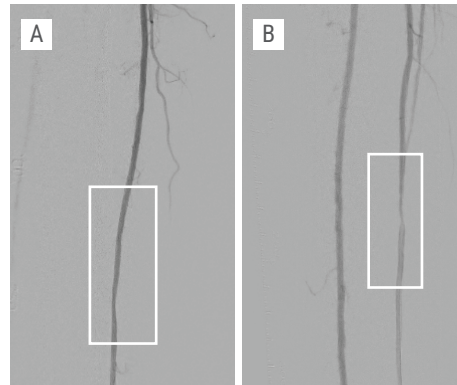


Figure 2

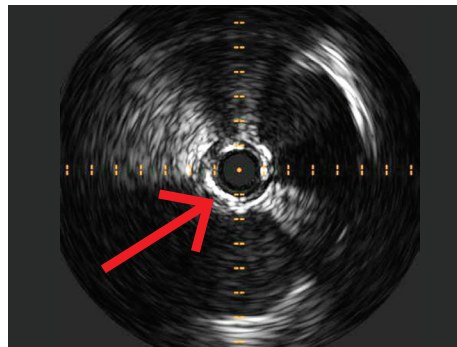


Figure 3

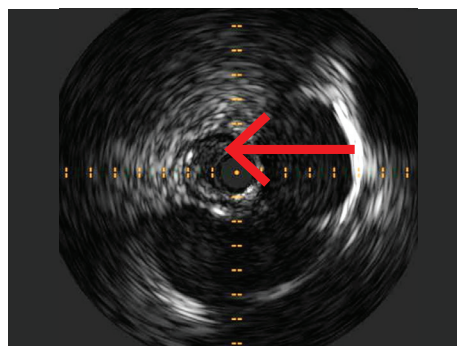


Figure 4

PHYSICIAN



Fadi A. Saab MD, FASE, FACC, FSCAI

Interventional Cardiologist, Medical Director, MOVI, Michigan Outpatient Vascular Institute, Dearborn, Michigan

"Post-Spur IVUS showed vessel compliance was restored and increase in acute luminal diameter."

Dr. Saab is board-certified in cardiovascular medicine and interventional cardiology, specializing in endovascular revascularization of peripheral vascular disease and critical limb ischemia. Dr. Saab is a course director for the Amputation Prevention Symposium, board member of the Outpatient Endovascular and Interventional Society and the Multidisciplinary Outpatient Cardiovascular Association and an active member of the CLI Global Society.

PRODUCTS USED



PERIPHERAL RETRIEVABLE STENT SYSTEM

Spur® RST Modifies Calcification and Disrupts Lamina

IVUS POST SPUR TREATMENT

Post Spur treatment, IVUS was repeated, demonstrating circumferential disruption in what was previously the medial wall calcium ring of the peroneal artery (Figure 6). Lumen now open with vessel pulsatility; vessel compliance re-established.

RESULTS

Post angiogram shows resolution of the stenotic lesion. Site reported post-stenosis <30%, core lab adjudicated 26%, with several new branches filling into the foot's digits after Spur treatment (Figure 7) compared to baseline angiogram (Figure 8).

At 3 months, the wound of the 4th digit was healed (Figure 9) and ABI unchanged, suggesting inaccurate result due to medial wall calcification. TBI increased from 0.68 (baseline) to 0.85 at 3-month follow up and 1.03 at 6 months. Rutherford Class 0 through 12-month follow up.

CONCLUSION

Vessel patency confirmed at 6 and 12 months with duplex ultrasound (Figure 10).

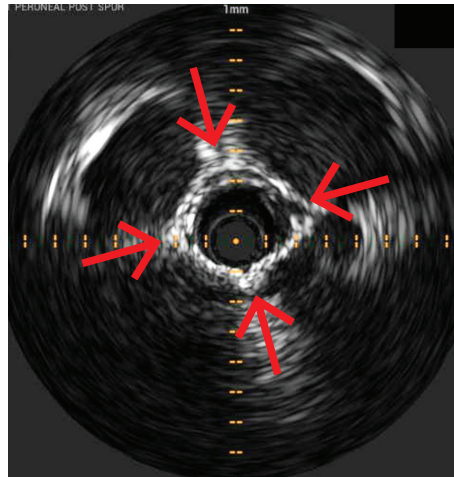


Figure 6

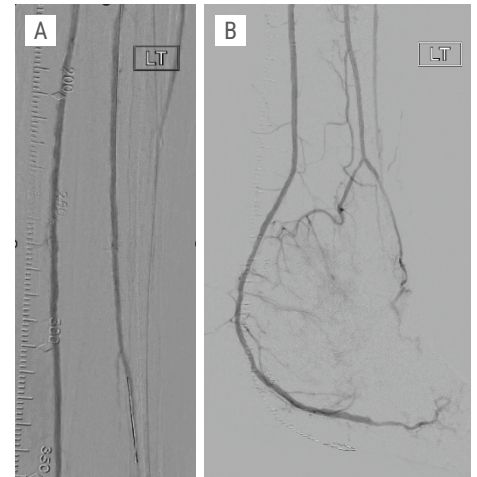


Figure 7

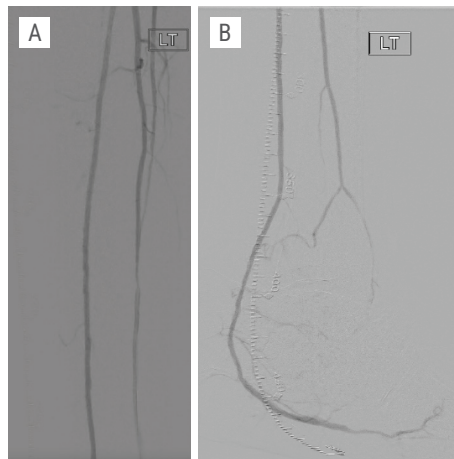


Figure 8

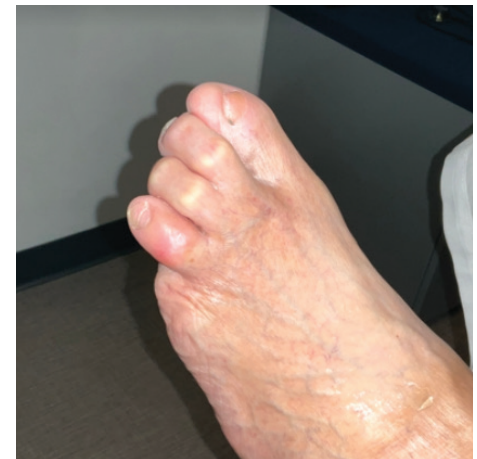

Figure 9

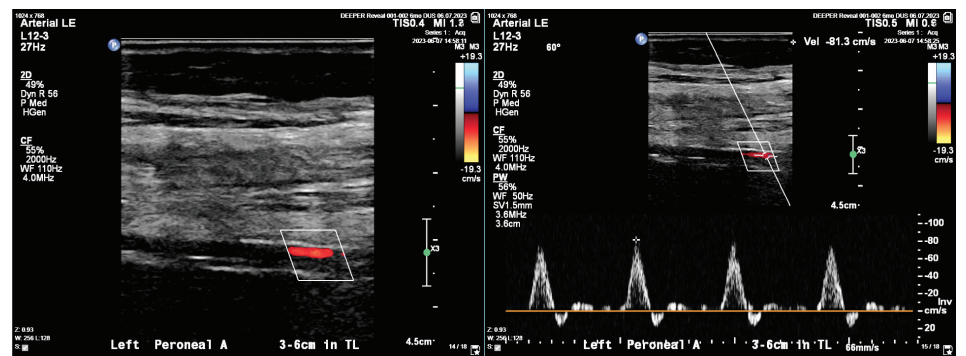


Figure 10