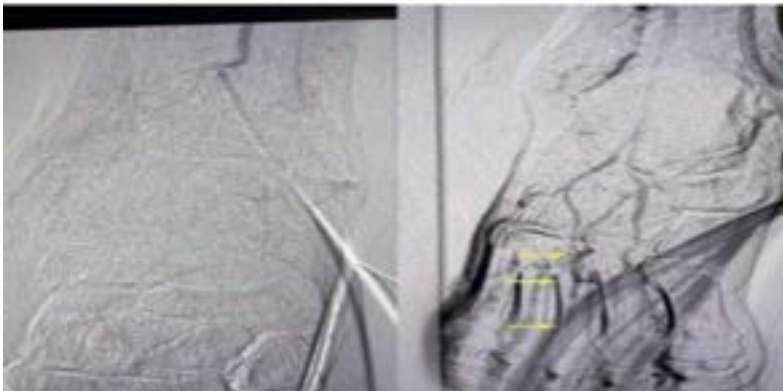
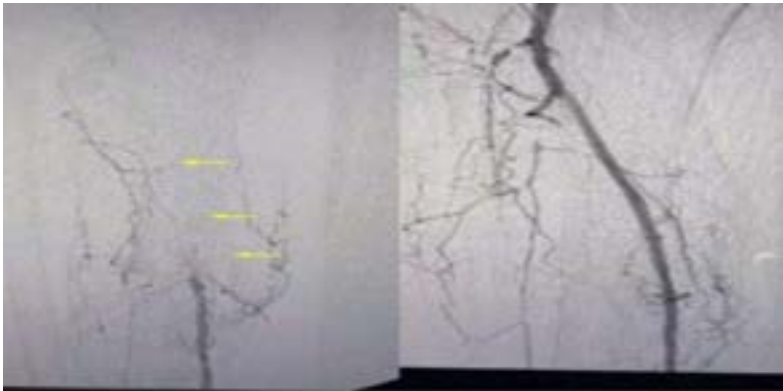


Wingman™ Used to Cross Long SFA CTO

CASE HISTORY

A 74-year-old male with a history of type 2 diabetes, hypertension, morbid obesity, and atherosclerosis of the bilateral extremities presented with an ulcer on the right plantar aspect and a gangrenous third digit on the right foot.



Baseline angiography

PROCEDURE

Ultrasound-guided access to the right distal posterior tibial artery was obtained in a retrograde manner and a 5/6 F Terumo Slender® sheath was placed. An angiogram was then performed. The superficial femoral artery (SFA) was found to be occluded along its entire length. Heavy calcification was noted in multiple areas. The right popliteal artery also appeared to be heavily calcified. An Asahi Mongo® guidewire and a NaviCross® microcatheter were inserted into the sheath and used to cross the lesion in the posterior tibial artery. The wire was switched to a stiff-angled Glidewire® in an attempt to cross the CTO cap at the adductor canal, without success. A 0.035" 135 cm Wingman™ catheter was used to fenestrate the distal cap multiple times, which allowed the guidewire to pass through the proximal cap. The wire was then exchanged for a Mongo.

PHYSICIAN



Siddhartha Rao, MD, RPVI

Interventional Cardiologist,
Vascular Solutions of North
Carolina

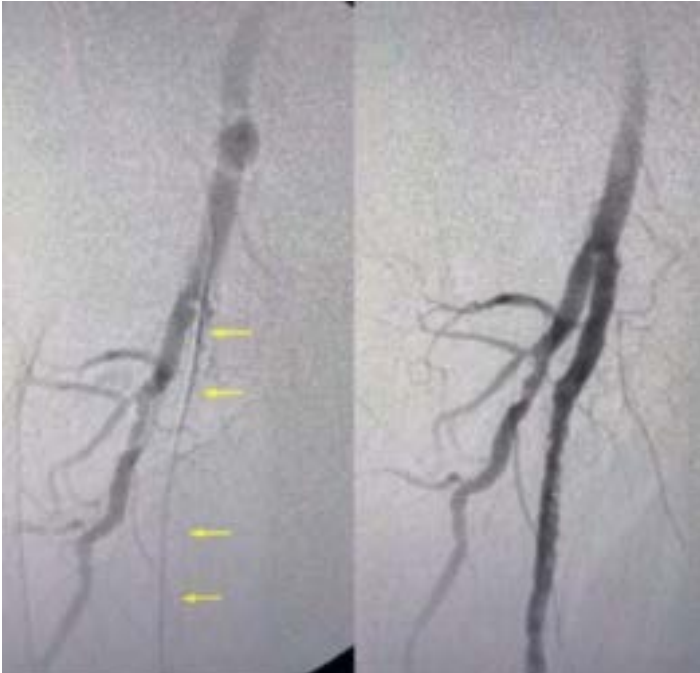*"The Wingman made the
difference in this case."*

Dr. Rao graduated with honors in 1998 from one of the most competitive medical schools, Jawaharlal Institute of Postgraduate Medical Education & Research (JIPMER), located in Pondicherry, India. He served as Chief Medical Resident from 2003–2004 after finishing a three-year Internal Medicine residency at Wayne State University in Detroit, MI. He finished a three-year Cardiology Fellowship followed by a one-year Interventional Cardiology fellowship at the University of North Carolina, Chapel Hill, NC. He obtained additional training in interventional vascular procedures at Ochsner Medical Center in New Orleans, LA and Prairie Cardiovascular, Springfield, IL. Dr. Rao is the founder and operator of Vascular Solutions of North Carolina.

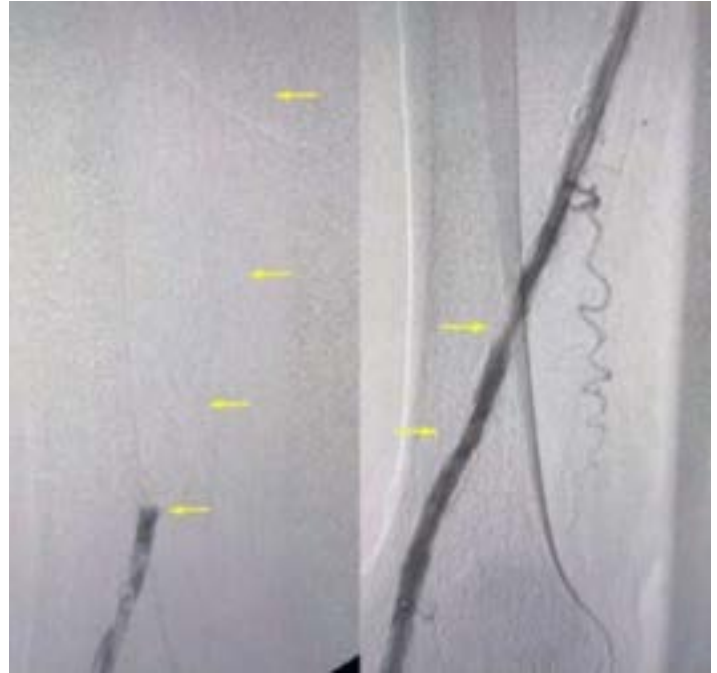
PRODUCTS USED



Wingman™ Facilitates CTO Cap Crossing



Pre/post right proximal-mid SFA

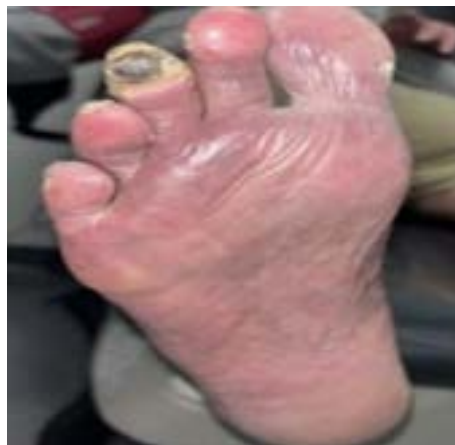

Pre/post right distal SFA and proximal popliteal artery

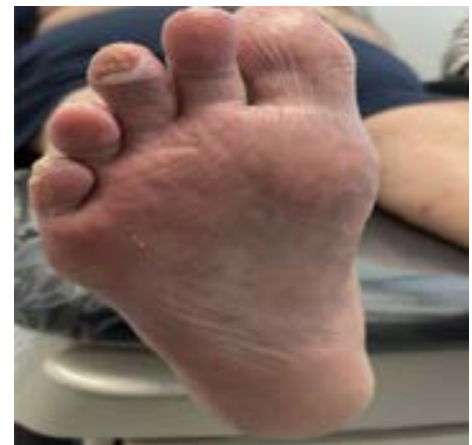The posterior tibial artery was ballooned and ultrasound was used to evaluate the vessel. A Phoenix 2.2mm atherectomy device was used on the entire femoropopliteal segment, followed by balloon angioplasty with a 6.0 X 240mm balloon. Repeat IVUS revealed a subintimal flap at the ostium of the anterior tibial artery and an Absolute Pro™ stent was placed.

CASE CONCLUSION

Successful revascularization of the SFA and the right tibial and popliteal artery was accomplished. TIMI-3 flow was restored to the area. “The Wingman was indispensable in helping us cross this 300mm SFA CTO in nine minutes from a primary pedal route, all while staying true lumen,” said Dr. Rao. “It allowed us to perform atherectomy and stenting, resulting in a polyphasic flow in the common plantar artery after the case.” At the two-month follow-up visit, the patient continued to have patency of revascularized segments and notable wound healing.



Pre-procedure



2-month followup